

## SPERMATOTOXIC EFFECTS OF AFLATOXIN B<sub>1</sub> IN A SAMPLE OF SOHAG POPULATION AND IN RABBITS

*BY*

**Soheir A. Mohamed, Khaled E. Abo-Elhagag, Maha A. Hilal, Eman  
M.S. Mohamed\* and Noha E. Osman\***

*Forensic Medicine & Clinical Toxicology and \* Histopathology Departments, Faculty of Medicine, Sohag University, Egypt*

### ABSTRACT

*Aflatoxins (A-flavus-toxins) are the most studied group of mycotoxins. At smaller concentrations the Aflatoxins can affect male reproduction, namely spermatogenesis. The present study was designed to investigate the effect of Aflatoxin-B<sub>1</sub> on male reproductive system by two ways: clinically on human beings and experimentally on rabbits. Human study was conducted on 100 males attending outpatients of Andrology Clinic of Sohag University Hospitals; 50 males had normal seminogram and 50 males had abnormal seminogram. Animal study was conducted on 45 adult NZW rabbit bucks. They were divided into three groups. Each group was divided to three subgroups; (negative control, positive control and treated rabbits). Treated subgroups received Aflatoxin B<sub>1</sub> by i.p injection at 20 µg/ kg/BW per day (subtoxic dose) for different durations (30 days, 48 days and 63 days). Human study showed significant increase in seminal plasma Aflatoxin-B<sub>1</sub> level in the infertile group. The increased AFB<sub>1</sub> level affected significantly semen parameters. Experimental results showed significant negative correlation between the seminal AFB<sub>1</sub> level and sperm concentration, sperm viability and total sperm motility but showed significant positive correlation with abnormal sperm forms. Histopathological examination showed degeneration of seminiferous tubules. The tubules showed absence of mature sperms with appearance of uninucleated and multinucleated giant cells. Epididymal epithelium showed vaculation and degeneration. From the obtained results, it can be concluded that Aflatoxin B<sub>1</sub> affect male reproductive system functionally and pathologically.*

### INTRODUCTION

Aflatoxins (A-flavus-toxins) are the most studied group of mycotoxins and are produced by different species of the genus *Aspergillus* (Bennett and

Klich, 2003).

Mycotoxins contaminate food by two general routes direct and indirect. Direct contamination occurs as a result of mould growth on food itself. The data

refer to the presence of Aflatoxins in corn, soyabean, groundnut, edible nuts spices and medicinal plants, milk and milk products, water and eggs. Indirect contamination of food occurs as a result of using food ingredient contaminated with mycotoxins. Probably no edible substance can be regarded as absolutely safe from possible Aflatoxin contamination (Zohri, 1990). Aflatoxin is associated with both toxicity and carcinogenicity in human and animals. Aflatoxin B<sub>1</sub> is the most potent natural carcinogen known and is usually the major Aflatoxin produced by toxigenic strains (Peterson et al., 2001). The diseases caused by Aflatoxin consumption are loosely called aflatoxicoses. Acute aflatoxicosis results in death (Bennett and Klich, 2003).

At smaller concentrations, Aflatoxin-B<sub>1</sub> (AFB<sub>1</sub>) in particular, can affect male reproduction. It produces changes varied from mild testicular degeneration to a complete atrophy of seminiferous tubules and loss of all stages of spermatogenesis. It also affects Leydig cell function and so affects fertility (Agnes and Akbarsha, 2003; Ahmed et al., 2012).

#### **Aim of the work**

The present study was designed to investigate the effect of Aflatoxin-B<sub>1</sub> on male reproductive system clinically on human beings and experimentally on rabbits.

## **SUBJECTS AND METHODS**

### **Patients**

The present study was conducted on 100 male attending outpatient andrology clinic of Sohag University Hospitals. Informed written consent was taken from every patient according to the guide approved by ethical committee of Faculty of Medicine, Sohag University.

### **Inclusion criteria**

Age of the patients was 20-50 years old with infertility for at least one year.

### **Exclusion criteria**

Other causes of infertility: radiation, heat exposure, drug abuse, abnormal hormonal assay, genital trauma or surgery, genital infections, mumps, febrile illness, testicular torsion or cryptorchidism, no azoospermia, no significant pyospermia. Wife factors were excluded by a gynecologist.

Patients were classified according to their seminogram into two groups. The first group (50 males) had normal seminogram. The second group (50 males) had abnormal seminogram.

### **Animals**

The present work was carried on 45 adult NZW rabbit bucks. Rabbits were found to be suitable animals for the present research as they are excellent

models for many aspects of research in reproductive toxicology (Morton, 1988). Male rabbit is the smallest, least expensive animal that can be ejaculated with an artificial vagina, permitting longitudinal evaluation of semen (Sun and Gondos, 1986).

Rabbits were seven-month-old with three kilograms average body weights. The ethics and husbandry conditions of animal research were considered according to the guides approved by ethical committee of Faculty of Medicine, Sohag University. Animals were purchased from animal house, Faculty of Agriculture, Assiut University. They were housed in animal house, Faculty of Medicine, Sohag University, Egypt, with room temperature being maintained ( $25 \pm 2$  °C). All bucks were daily exposed to 16 continuous lighting hours and individually housed in wire galvanized cages as well as fed on a commercial pelleted breeder.

The experiment lasted for 63 days from March to May, 2010 to investigate effects of AFB<sub>1</sub> (International Rabbit Reproduction Group, 2005).

The 45 NZW rabbit bucks were divided into three groups, 15 rabbits each according to the method modified from (Faridha et al., 2006) and according to rabbit's cycle (Sun and Gondos, 1986). Each group was divided into three subgroups; five rabbits

each (negative control, positive control and treated rabbits).

**Negative control:** Received the commercial rabbit ration only.

**Positive control:** Received the vehicle [corn oil and ethanol (95:5)] by intraperitoneal (i.p.) injection.

**Treated subgroups:** Received Aflatoxin B<sub>1</sub> by i.p. injection at 20 µg/ kg B.W. per day (subtoxic dose) (Salem et al., 2001) for different durations according to the group.

- In the first group: Rabbits received Aflatoxin B<sub>1</sub> for 30 days.
- In the second group: Rabbits received Aflatoxin B<sub>1</sub> for 48 days.
- In the third group: Rabbits received Aflatoxin B<sub>1</sub> for 63 days.

#### Material

• Aflatoxin B<sub>1</sub> for injection was obtained as a gift from Dr. Esmail El-Kady Professor of Botany, Faculty of Science, Assiut University. It was prepared in corn oil and ethanol (95:5) according to (Egbunike et al., 1980).

• Aflatoxin B<sub>1</sub>(AFB<sub>1</sub>) analytical standard for High Performance Liquid Chromatography (HPLC) was obtained from SIGMA chemical CO. (one µg/ ml).

• Methanol, acetonitrile, hexane, chloroform, formic acid, potassium dihydrogen phosphate (KH<sub>2</sub>PO<sub>4</sub>) and trifluoroacetic acid (TFA), HPLC grade purchased from SIGMA chemical CO.

- A 7.4 pH buffer was prepared in So-hag clinical toxicology laboratory. The pH was adjusted by pH-meter.

- Picric acid, formol, glacial acetic acid, ethyle alcohol, xylene from Biochem for laboratory chemicals.

- Hematoxyline and Eosin stains from ALPHACHEMIKA.

### Instruments

- High Performance Liquid Chromatography (HPLC) system consisted of Waters Binary Pump Model 1525, a Model Waters 1500 Rheodyne manual injector, a Watres 2475 Multi-Wavelength Fluorescence Detector, Nova-Pak C18 Column, 60Å, 4 µm, 3.9 mm X 150 mm and a data workstation with software Breeze 2 in Mycotoxins Central Lab and Food Safety, National Research Center, Egypt.

- Olympus CX 41 RF light field microscopy.

- Vortex VM300, Gemy industrial crop.

- Centrifuge EBA20, 5000 RPM, Hettich Zentifugen.

- pH-meter HANNA (pH211).

- Human Power One water deionizer.

- Rotator SB3, Bibby Scientific.

- DQ world hemocytometer

- Micro pipette (2-20 µl), Pipetman Neo-p2ON, Gilson.

- Artificial vagina manually made by technician according to character shown in (Louis-Marie and Jaingline, 2009) (Figure 1).



Fig. (1) : Artificial vagina for collection of semen from rabbits.

### Methods

#### I-Collection and preparation of semen samples:

##### a) Human semen samples:

Semen samples were collected from patients by masturbation. Complete seminogram was done according to WHO laboratory manual for the examination and processing of human semen (World Health Organization and Department of Reproductive Health and Research, 2010). The seminal plasma was obtained by centrifugation at 5000 rpm for 10 minutes and stored in -20 °C until analysis for Aflatoxin B<sub>1</sub> level.

##### b) Animal semen samples:

Ejaculate samples were collected from each group of animals at the beginning and at the end of the study using a clean, dried and sterilized standard artificial

vagina of rabbits and a teaser doe. The temperature of the artificial vagina was adjusted by warm water to be 41- 43.0 °C. Pressure required for ejaculation was obtained by blowing air through the valve after the water has been inserted in. The artificial vagina was lubricated by applying a layer of a thin coating of sterile white Vaseline.

The volume of each ejaculate was recorded using a graduated collection tube after gel mass removal. Sperm concentration per ml ( $\times 10^6$ ) was calculated using a weak eosin (5%) solution by hemocytometer. Ten microliters from the sample were taken by a micropipette, and then were diluted to one milliliter. The sample was spread at hemocytometer under coverslip. The sperms were counted using 400 X (magnification) (40 X objective lens). The number of sperms was counted at one millimeter square ( $=0.1\mu\text{l}$ ). The total number of sperms was calculated by multiplying dilution factor ( $100 \times 10^4$ ) to determine the number of sperms per milliliter (Smith and Mayer, 1955).

Assessment of viability and abnormal sperm forms was performed using an eosin staining then calculated as a percentage out of randomly chosen 100 sperm counted. Total sperm motility (%) was estimated by taking a drop of freshly collected semen. Then it was placed on a slide

and the percentage of motile sperm was estimated by visual examination under low-power magnification (10 X). The seminal plasma was separated by centrifugation at 5000 rpm for 10 minute and stored in -20 °C until analysis for Aflatoxin B<sub>1</sub> level.

## II. Histopathological examination

At the end of the study, rabbits were sacrificed by cut throat and dissected to expose the testis and epididymis for histopathological examination with light field microscopy. Right testis from control and treated animals were dissected and fixed in Bouin solution (75 ml saturated solution of picric acid, 25 ml of 40 % formol and 5 ml glacial acetic acid). The specimens were stained by Hematoxyline and Eosin.

## III-Histometric analysis

Fields with seminiferous tubules (STs) in circular transverse sections were selected at 100 X. Using the software, the boundary of each was demarcated. The percentage of both seminiferous tubules area and interstitial area was calculated as the following:

Total area of the field = width x length of the field.

Interstitial area = total area of the field – STs.

Percentage of STs = STs area / total area of the field x100.

Percentage of interstitial area = interstitial area / total area of the field x 100.

This was done for five different fields for each rabbit, thus making 25 measurements for each sub-group.

#### IV-Quantitative analysis of Aflatoxin B<sub>1</sub> for both humans and rabbits:

##### Extraction of seminal plasma:

Determination of Aflatoxin B<sub>1</sub> in seminal plasma was done by a method which was modified from that recorded by Corcuera et al. (2011). One ml of acetonitrile was added to one ml of seminal plasma. The tube was rotated for 20 minute and centrifuged for five minutes. The supernatant was separated into another tube. Half ml of 7.4 pH buffer and six ml of hexane was added to the supernatant. The tube was rotated for 20 minute and then the upper layer was discarded. Again, 0.5 ml 7.4 pH buffer was added to the residue and six ml chloroform was added. The tube was rotated for 20 minute and then

the upper layer was discarded. The chloroform was evaporated. The extracted samples were derivatized and analyzed by High Performance Liquid Chromatography (HPLC).

##### Statistical analysis

The data obtained were analyzed statistically using SPSS (Statistical Program for Social (SPSS inc. Chicago, Illinois, USA). Mean and standard deviation (SD) were calculated. Student T-test and one-way of variance (ANOVA) test was performed. Significant difference was at p value < 0.05.

## RESULTS

##### The results of human study

Figure (2) shows HPLC chromatogram of Aflatoxin B<sub>1</sub> standard (area and retention time). Aflatoxin B<sub>1</sub> was detected at retention time five. Concentrations of samples were calculated from calibration area of the standard (Figure 3).

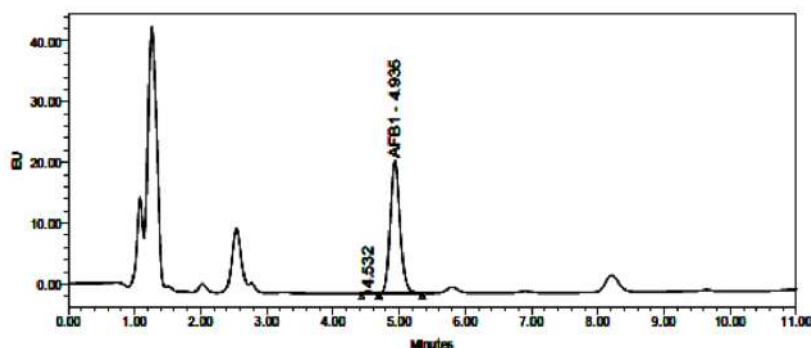


Fig. (2) : HPLC chromatogram for Aflatoxin B<sub>1</sub> standard (area and retention time).

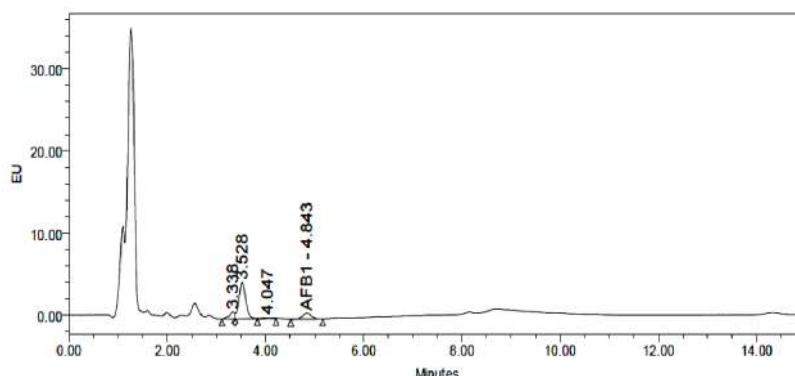


Fig. (3) : HPLC chromatogram of Aflatoxin B<sub>1</sub> (area and retention time) in a human semen sample .

The present study showed no significant statistical differences in the mean value of age and the mean value of seminal fluid volume between the first and second human groups ( $p > 0.05$ ). There were significant decreases in sperm concentration per milliliter, progressive sperm motility and total sperm motility in the second

group as compared with the first group ( $p < 0.001$ ). On the other hand, there was significant increase in the mean value of abnormal sperm forms, and significant increases in the mean values of seminal plasma AFB<sub>1</sub> level in the second group as compared with the first human group ( $p < 0.001$ ) (Table1).

Table (1) : Mean values of age, seminal fluid parameters and seminal plasma AFB<sub>1</sub> level in the first and second groups of the studied human cases (n = 100).

Parameters		Group		p-value
		Normal seminogram (first group)	Abnormal seminogram (second group)	
		Mean ± SD	Mean ± SD	
Age (year)		33±7	35 ± 7	0.19
Semen parameters	Seminal fluid volume (ml)	2.77 ± 0.91	2.48 ± 0.98	0.13
	Sperm concentration per ml ( $\times 10^6$ )	93.37±29.72	16.61±13.23	0.000 *
	Progressive sperm motility (%)	62.90±15.01	27.43±16.65	0.000 *
	Total sperm motility (%)	80.78±10.13	43.12±18.70	0.000 *
	Abnormal sperm forms (%)	37.52±18.41	67.86±16.10	0.000*
Seminal plasma AFB <sub>1</sub> level (pg/ml)		39±37	260±140	0.000 *

n: number, \* significant at  $p < 0.05$ , SD: Standard deviation, AFB<sub>1</sub>: Aflatoxin B<sub>1</sub>.

**Table (2) :** Correlation between seminal plasma AFB<sub>1</sub> (pg/ml) and different seminal fluid parameters in the second human group (had abnormal seminogram) (n = 50).

Parameters	Seminal plasma AFB <sub>1</sub>	
	Correlation coefficient	p-value
Seminal fluid volume (ml)	-0.051	0.6
Sperm concentration per ml ( $\times 10^6$ )	- 0.59	0.000*
Progressive motility (%)	- 0.6	0.000*
Total motility (%)	- 0.6	0.000*
Abnormal sperm forms (%)	0.7	0.000*

n: number, \* significant correlation at  $p < 0.05$ , AFB<sub>1</sub>: Aflatoxin B<sub>1</sub>.

Table (2) shows the correlation between seminal plasma AFB<sub>1</sub> level and different seminal fluid parameters in the studied human cases [seminal fluid volume, sperm concentration, progressive sperm motility, total sperm motility and abnormal sperm forms]. There was no significant correlation between seminal plasma AFB<sub>1</sub> level (pg/ml) and seminal fluid volume ( $r = - 0.051$ ;  $p > 0.05$ ). There were significant negative correlations between seminal plasma AFB<sub>1</sub> level and sperm concentration, progressive sperm motility and total sperm motility ( $r = - 0.59$ ,  $- 0.6$  and  $- 0.6$  respectively;  $p < 0.001$ ). On the other hand a significant positive correlation was found between seminal plasma AFB<sub>1</sub> level and abnormal sperm forms ( $r = 0.7$ ;  $p < 0.001$ ).

### Experimental study results

As regard the first group of rabbit

bucks, there were no significant statistical differences in the mean values of seminal fluid volume, sperm concentration, sperm viability, sperm motility, abnormal sperm forms in the post-treatment rabbits as compared with the negative control, positive control and pre-treatment rabbits ( $p > 0.05$ ). On the other hand there was significant increase in the mean value of seminal plasma AFB<sub>1</sub> level in the post-treatment rabbits as compared with the negative control, positive control and pre-treatment rabbits ( $p < 0.001$ ) (Table 3).

The second group of rabbit bucks showed no statistical significant difference in the mean values of seminal parameters in the post-treatment rabbits as compared with the negative control, positive control and pre-treatment rabbits ( $p > 0.05$ ). As regard the seminal plasma AFB<sub>1</sub> level in the second group of rabbit bucks, there was



significant increase in seminal plasma AFB<sub>1</sub> level in the post-treatment rabbits as compared with the negative control, positive control and pre-treatment rabbits (p < 0.001) (Table 4).

The results of the third group of rabbit bucks showed no statistical significant difference in the mean values of seminal fluid volume in the post-treatment rabbits as compared with the negative control, positive control and pre-treatment rabbits (p > 0.05). There were significant decreases

in sperm concentration, sperm viability and total sperm motility in the post-treatment rabbits. Also a significant increase in the mean value of abnormal sperm forms was found in the post-treatment rabbits as compared with the negative control, positive control and pre-treatment rabbits. There was significant increase in the mean value of seminal plasma AFB<sub>1</sub> level in the post-treatment rabbits as compared with the negative control, positive control and pre-treatment rabbits (p < 0.001) (Table 5).

**Table (3) :** Mean values of seminal fluid parameters and seminal plasma AFB<sub>1</sub> level in the first group of rabbit bucks (received Aflatoxin B<sub>1</sub> for 30 days) (n = 15).

Parameters		Negative control	Positive control	First group		P-value		
				Mean ± SD	Mean ± SD	Pre-treatment	Post-treatment	Post-treatment versus negative control
		Mean ± SD	Mean ± SD					
Semen parameters	Seminal fluid volume (ml)	0.94 ± 0.09	0.9 ± 0.07	0.940 ± 0.089	0.880 ± 0.084	0.72	0.69	0.62
	Sperm concentration per ml (×10 <sup>6</sup> )	225 ± 7.9	224 ± 6.5	230 ± 12.75	224.6 ± 6.52	0.83	1.00	0.32
	Sperm Viability (%)	83 ± 3.5	83 ± 2.5	80.0±3.54	79 ± 4.18	0.1	0.07	0.62
	Total sperm motility (%)	70 ± 3.5	68 ± 2.7	67 ± 4.18	66 ± 2.73	0.14	0.4	0.62
	Abnormal sperm forms (%)	15 ± 3.54	16 ± 2.23	17 ± 4.47	17 ± 2.74	0.35	0.54	1.00
Seminal plasma AFB <sub>1</sub> level (pg/ml)		ND	ND	ND	217± 13	0.000*	0.000*	0.000*

n: number, \*significant difference at p < 0.05, ND: not detected, SD: Standard deviation, AFB<sub>1</sub>: Aflatoxin B<sub>1</sub>.

**Table (4) :** Mean values of seminal fluid parameters and seminal plasma AFB<sub>1</sub> level in the second group of rabbit bucks (received Aflatoxin B1 for 48 days) (n = 15).

Parameters		Groups		Second group		P-value		
		Negative Control	Positive control	Pre-treatment	Post-treatment	Post-treatment versus negative control	Post-treatment versus positive control	Post-treatment versus pre-treatment
		Mean ± SD	Mean ± SD	Mean ± SD	Mean ± SD			
Semen parameters	Seminal fluid volume (ml)	0.9 ± 0.12	0.9 ± 0.06	0.94 ± 0.089	0.92 ± 0.084	0.77	0.67	0.62
	Sperm concentration per ml (×10 <sup>6</sup> )	227 ± 7.58	226 ± 4.18	225 ± 6.21	221 ± 2.34	0.13	0.2	0.2
	Sperm viability (%)	81 ± 4.18	79 ± 4.2	77.0 ± 4.47	76 ± 3.54	0.10	0.14	0.18
	Total sperm motility (%)	67 ± 2.7	66 ± 4.18	66.0 ± 2.24	65 ± 2.74	0.08	0.11	0.09
	Abnormal sperm forms (%)	16 ± 2.2	17 ± 2.7	16.0 ± 4.18	19 ± 4.18	0.2	0.4	0.07
Seminal plasma AFB <sub>1</sub> level (pg/ml)		ND	ND	ND	451 ± 8	0.000*	0.000*	0.000*

n: number, \*significant difference at p < 0.05, ND: not detected, SD: Standard deviation, AFB1: Aflatoxin B<sub>1</sub>.

**Table (5) :** Mean values of seminal fluid parameters and seminal plasma AFB<sub>1</sub> level in the second group of rabbit bucks (received Aflatoxin B<sub>1</sub> for 48 days) (n = 15).

Parameters		Groups		Third group		P-value		
		Negative Control	Positive control	Pre-treatment	Post-treatment	Post-treatment versus negative control	Post-treatment versus positive control	Post-treatment versus pre-treatment
		Mean ± SD	Mean ± SD	Mean ± SD	Mean ± SD			
Semen parameters	Seminal fluid volume (ml)	0.92 ± 0.23	0.89 ± 0.07	0.92 ± 0.192	0.88 ± 0.084	0.72	0.8	0.54
	Sperm concentration per ml (×10 <sup>6</sup> )	220 ± 9.35	227 ± 9.08	222 ± 5.70	160 ± 41.83	0.01*	0.008*	0.03 *
	Sperm viability (%)	85 ± 3.5	84 ± 2.24	83 ± 2.72	56.0 ± 8.94	0.000*	0.000*	0.001 *
	Total sperm motility (%)	66.2 ± 5.45	67 ± 4.38	70 ± 3.54	50 ± 7.07	0.004*	0.002*	0.005*
	Abnormal sperm forms (%)	16 ± 2.24	16 ± 2.23	17.0 ± 2.74	27 ± 4.47	0.001*	0.001*	0.01 *
Seminal plasma AFB <sub>1</sub> level (pg/ml)		ND	ND	ND	612 ± 23	0.000*	0.000*	0.000*

n: number, \*significant difference at p < 0.05, ND: not detected, SD: Standard deviation, AFB1: Aflatoxin B<sub>1</sub>.

In the current study, there was neither significant statistical difference in the mean value of seminal fluid volume between the first and second group treated rabbits, first and third group, the second and third group nor different treated rabbits groups ( $p > 0.05$ ). There were no significant statistical differences in the mean value of sperm concentration, sperm viability and total sperm motility between the first and second group treated rabbits, but there was significant decrease between the first and third group treated rabbits, the second and third group and different treated animal groups. For the mean values of abnormal sperm forms, there was no significant statistical difference be-

tween the first and second group treated rabbits ( $p > 0.05$ ) but there was significant increase between the first and third group treated rabbits ( $p < 0.01$ ), the second and third group treated rabbits ( $p > 0.05$ ) and different treated rabbit groups ( $p < 0.01$ ) (Table 6).

As regard the mean value of seminal plasma AFB<sub>1</sub> level, there were significant statistical differences between the first and second group treated rabbits, the first and third group treated rabbits, the second and third group treated rabbits and different treated rabbit groups ( $p < 0.001$ ) (Table 6).

**Table (6) :** Comparison of mean values of seminal fluid parameters of the rabbit bucks among the three studied groups after AFB<sub>1</sub> treatment (n = 45).

Groups Parameters		First group	Second group	Third group	P value			
		Mean ± SD	Mean ± SD	Mean ± SD	First versus second group	First versus third group	Second versus third group	ANOVA
Semen parameters	Seminal fluid volume (ml)	0.92 ± 0.084	0.92 ± 0.084	0.88 ± 0.084	1.00	0.47	0.47	0.69
	Sperm concentration per ml (×10 <sup>6</sup> )	224.6 ± 6.52	221 ± 2.34	160 ± 41.83	0.36	0.01 *	0.01 *	0.002 *
	Sperm viability (%)	79 ± 4.18	75 ± 3.54	56 ± 8.94	0.14	0.001 *	0.002 *	0.000 *
	Total sperm motility (%)	66 ± 2.73	62 ± 2.74	50 ± 7.07	0.11	0.002 *	0.008 *	0.001 *
	Abnormal sperm forms (%)	17 ± 2.74	19 ± 4.18	27 ± 4.47	0.4	0.003 *	0.019 *	0.004 *
Seminal plasma AFB <sub>1</sub> level (pg/ml)		217 ± 13	451 ± 8	612 ± 23	0.000 *	0.000 *	0.000 *	0.000 *

n: number, \*significant difference at  $p < 0.05$ , ND: not detected, SD: Standard deviation, AFB<sub>1</sub>: Aflatoxin B<sub>1</sub>.

**Table (7) :** Correlation between seminal plasma AFB<sub>1</sub> (pg/ml) and different seminal fluid parameters in the AFB<sub>1</sub> treated rabbit bucks (n = 15).

Parameters	Seminal plasma AFB <sub>1</sub>	
	Correlation coefficient	P-value
Seminal fluid volume (ml)	- 0.27	0.37
Sperm concentration per ml (×10 <sup>6</sup> )	- 0.68	0.005 *
Sperm viability (%)	- 0.78	0.001*
Total sperm motility (%)	- 0.79	0.000 *
Abnormal sperm forms (%)	0.67	0.006 *

n: number, \* significant difference at p < 0.05, AFB<sub>1</sub>: Aflatoxin B<sub>1</sub>.

Table (7) shows the correlation between seminal plasma AFB<sub>1</sub> level and different seminal fluid parameters in the AFB<sub>1</sub> treated rabbit bucks. There was no significant correlation between seminal AFB<sub>1</sub> level and plasma seminal fluid volume (r = - 0.27 and p > 0.05). There were significant negative correlations between plasma seminal AFB<sub>1</sub> level and seminal concentration, sperm viability, sperm motility (r = - 0.68, - 0.78, - 0.79 and p < 0.01, 0.01 and 0.001 respectively). On the other hand, there was significant positive correlation between plasma seminal AFB<sub>1</sub> level and abnormal sperm forms (r = 0.67, p < 0.01).

**Histometric analysis**

In the first, second and third rabbit groups, there were significant decreases in the mean value of seminiferous tubules

area and significant increase in the interstitial area in the treated rabbits as compared with the negative and positive control groups (p < 0.01) (Table 8). By comparison between the three rabbit groups using AVOVA test, there were significant decrease in the mean seminiferous tubules area and significant increases in the mean value of interstitial area between the first and second group treated rabbits, the first and third group treated rabbits, the second and third group treated rabbits and different treated animal groups (p < 0.01) (Table 9).

In the current study, there was significant negative correlation between seminal plasma AFB<sub>1</sub> level and seminiferous tubules area (r = -0.9 and p < 0.01) while positive correlation between seminal plasma AFB<sub>1</sub> level and interstitial area (r = 0.9 and p < 0.01) was detected (Table

**Table (8) :** Comparison of the mean value of histometric analysis between controls and AFB<sub>1</sub> treated rabbit groups ( n=45).

Groups Parameters		Negative control	Positive control	AFB <sub>1</sub> treated rabbits	P value		
		Mean ± SD	Mean ± SD	Mean ± SD	Negative control versus positive control	Treated groups versus negative control	Treated groups versus positive control
First Group	Seminiferous tubules area (%)	87.66 ± 1.77	85.8 ± 2.8	76.57 ± 2.24	0.611	0.000*	0.000*
	Interstitial area (%)	12.33 ± 1.77	14.15 ± 2.8	23.43 ± 2.24	0.611	0.000*	0.001*
Second Group	Seminiferous tubules area (%)	86.5 ± 1.6	87.3 ± 1.7	72.40 ± 1.24	0.471	0.000*	0.000*
	Interstitial area (%)	13.5 ± 1.6	12.7 ± 1.7	27.60 ± 1.24	0.471	0.000*	0.000*
Third Group	Seminiferous tubules area (%)	87.2 ± 2.4	87.7 ± 1.8	66.26 ± 1.72	0.72	0.000*	0.000*
	Interstitial area (%)	12.8 ± 2.4	12.3 ± 1.8	33.74 ± 1.72	0.72	0.000*	0.000*

n: number, \* significant difference at p < 0.05, AFB<sub>1</sub>: Aflatoxin B<sub>1</sub>.

**Table (9) :** Comparison of mean values of histometric analysis among different AFB<sub>1</sub> treated rabbit groups (n = 15).

Groups Parameters	First group	Second group	Third group	P-value			
	Mean ± SD	Mean ± SD	Mean ± SD	First versus second group	First versus third group	Second versus third group	ANOVA
Seminiferous tubules area (%)	76.57 ± 2.24	72.40 ± 1.24	66.26 ± 1.72	0.007*	0.000*	0.000*	0.000*
Interstitial area (%)	23.43 ± 2.24	27.60 ± 1.24	33.74 ± 1.72	0.007*	0.000*	0.000*	0.000*

n: number, \* significant difference at p < 0.05.

**Table (10) :** Correlation between seminal plasma AFB<sub>1</sub> (pg/ml) and histometric analysis in AFB<sub>1</sub> treated rabbit bucks (n = 15).

Parameters	Correlation co-efficient	P value
Seminiferous tubules area (%)	- 0.9	0.000*
Interstitial area (%)	0.9	0.000*

n: number, \* significant correlation at p < 0.05, AFB<sub>1</sub>: Aflatoxin B<sub>1</sub>

10).

### **Histopathological results**

#### **Testis**

Hematoxyline and Eosin examination of both negative and positive control groups revealed that, the testis was formed of seminiferous tubules that were lined with many layers of spermatogenic cells in addition to Sertoli cells. The interstitial tissue is formed of Leydig cells and blood capillaries (Figure 4).

Examination of the first group treated rabbits revealed that the tubules had an irregular outline. Most of the tubules contained many layers of spermatogenic cells up to sperms, others were devoid of them. Some spermatogenic cells contained dense pyknotic nuclei and vacuolated cytoplasm. The interstitial tissue showed edema and acidophilic exudates with congestion of blood vessels. The second group treated rabbit examination revealed that the tubules had an irregular outline. Some tubules were full of spermatogenic cells up to late spermatid which had an orientation in the form of their nuclei toward the base of the tubules. Other tubules had disorganized germ cells with pyknotic nuclei and vacuolated cytoplasm. The interstitial

tissue showed edema. The third group treated rabbits examination revealed that most of the tubules had irregular outline and contained few layers of germ cells with pyknotic nuclei and vacuolated cytoplasm (Figure 5). Few spermatids were observed with appearance of abnormal cells (mononucleated and multinucleated giant cell).

#### **The epididymis**

The epididymis of the control rabbits was formed of tubules lined with pseudo-stratified columnar ciliated epithelium. The lumen contained numerous sperms (Figure 6). Examination of the first group treated rabbits revealed that the epididymal tubules contained fewer number of spermatozoa compared to the control one. The second group treated rabbit examination showed that some cells lining the epididymal tubules had pyknotic nuclei and vacuolated cytoplasm while the epididymis of the third group treated rabbits showed shedding of parts of the epithelial lining. Examination of the third group treated rabbits revealed that some cells lining the epididymal tubules desquamated to form the basement membrane with no spermatozoa in the tubular lumen (Figure

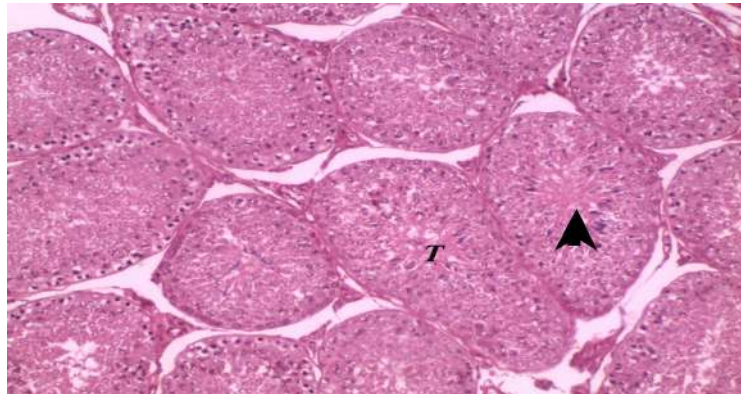


Fig. (4) : A photomicrograph of a section in the testis of control group showing many seminiferous tubules (T) with narrow lumina (arrows) (Hematoxyline and Eosin X 100).

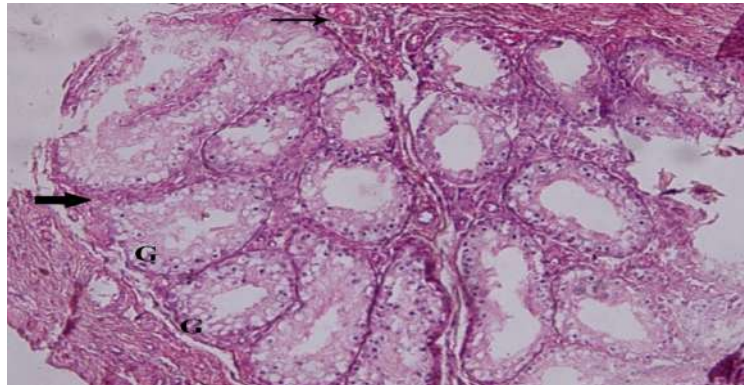


Fig. (5) : A photomicrograph of a section in the testis of the third treated group showing most of the tubules contains few layers of spermatogenic cells which had pyknotic nuclei and vacuolated cytoplasm (G) (Hematoxyline and Eosin X 200).

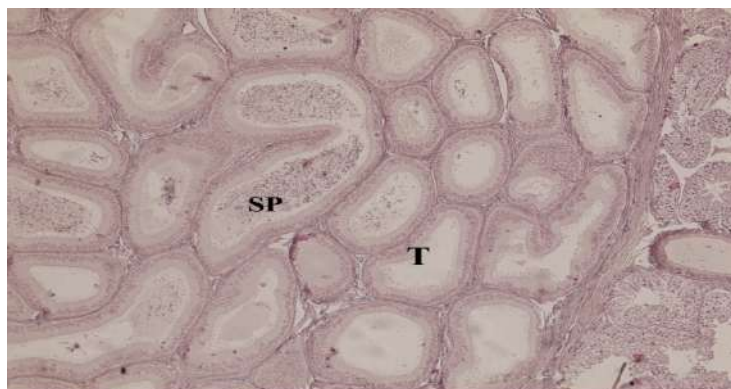


Fig. (6) : A photomicrograph of a section in the epididymis of the control rabbits showing numerous spermatozoa (sp) in its tubules (T) (Hematoxyline and Eosin X 200).

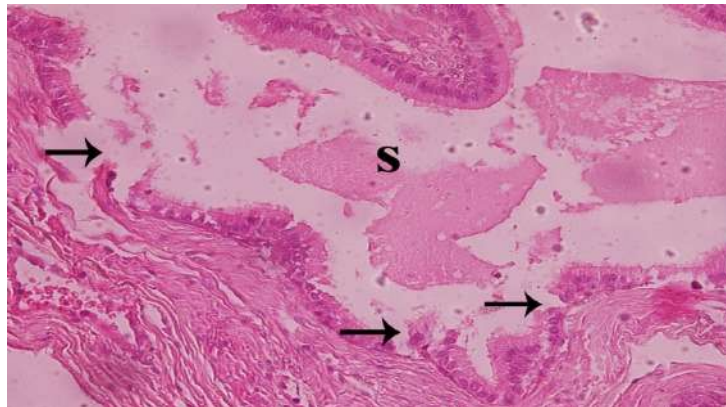


Fig. (7) : A photomicrograph of a section in the epididymis of the third treated group showing shedding of parts of the epithelial lining (arrows) (Hematoxyline and Eosin X 400).

7).

### DISCUSSION

Dietary toxins such as mycotoxins are among the major contributors to deterioration of male reproductive health (Hussein and Brasel, 2001).

The present case-control study showed significant decreases in the mean values of human sperm concentration, progressive sperm motility and total sperm motility in the second group. On the other hand, there were significant increases in the mean values of abnormal sperm forms, and seminal plasma AFB<sub>1</sub> level in the second group as compared with the first human group. Significant negative correlation between seminal plasma AFB<sub>1</sub> level and sperm concentration, progressive sperm motility and total sperm motility was found. On the other hand there was significant positive correlation between

seminal plasma AFB<sub>1</sub> level and abnormal sperm forms.

These results could be explained by the toxic effect of dietary exposure to Aflatoxins on spermatogenesis. De Kretser and Kerr (1994) recorded that on exposure to Aflatoxin, a significant alteration in progression of the cell cycle of spermatogenesis was observed. This alteration leads to damaging effect to the chromatin of pachytene spermatocytes. The metabolic processing of AFB<sub>1</sub> by cytochrome P450 generates the reactive intermediate exo-AFB<sub>1</sub>-8, 9-epoxide, which is capable of covalent binding to DNA to form bulky adducts. These adducts, if not repaired, may cause site-selected mutagenesis (Denissenko et al., 1999; Williams et al., 2004). Aflatoxins were also reported to interfere with protein synthesis by binding to both RNA and DNA and blocking transcription (Pier, 1992).



Adedara et al. (2014) reported that AFB<sub>1</sub> suppressed testosterone secretion in a dose-dependent manner and inhibited expression of cholesterol transporter steroidogenic regulatory protein (StAR) and steroidogenic enzymes. The finding highlights potential extra-hepatic effects of Aflatoxin exposure. Also it indicates that exposure to AFB<sub>1</sub> has significant reproductive health implications even under conditions of low dietary toxin levels.

The results are in agreement with Hafez et al. (1983) who studied the effect of dietary Aflatoxins on adult fertile male rabbits at various reproductive conditions. The results revealed an injurious effect on the reproductive performance in males that received high dietary Aflatoxins. It was found that Aflatoxin was secreted in the semen and conjugated with the gamma-globulin fraction of plasma proteins. Pícha et al. (1986) studied Aflatoxin B<sub>1</sub> and fertility in 21 boars of four breeds for the period of twelve months. It was found that the group of boars with fertility disorders had more Aflatoxin in their sperm (up to 100 pmol /l), lower sperm concentration, lower survival of spermatozoa, and a larger proportion of abnormal spermatozoa.

Another study was conducted by Uriah et al. (2001) on adult Nigerian individuals who found significant increase in Aflatox-

in B<sub>1</sub> in blood and semen of infertile men than in fertile ones. The mean levels of seminal plasma AFB<sub>1</sub> were higher than the mean levels in the present study. This increase can be explained by high environmental temperature in Nigeria which favors Aflatoxin formation.

As regard the first and second groups of rabbit bucks, there was no significant statistical difference in the semen parameters in the post-treatment rabbits as compared with the negative control, positive control and pre-treatment rabbits in spite of significant increase in the mean value of seminal plasma AFB<sub>1</sub> level in post-treatment rabbits.

Semen quality was not affected by the toxic effect of AFB<sub>1</sub> in the first and second rabbit group. This could be explained by the length of the spermatogenic cycle of the seminiferous epithelium in rabbits. In rabbit, each cycle lasts 10.7 days. Approximately 48 days or 4.5 cycles are required for committed type A spermatogonium to differentiate into mature spermatozoa. Then they are released into the lumen of seminiferous tubules. An additional 10-14 days (1-1.5 cycles) are required for spermatozoa to pass through the epididymis into the ejaculate (Amann, 1982).

As regard the third group rabbit bucks, there was significant decrease in the mean value of sperm concentration, sperm via-

bility, and total sperm motility in the post-treatment rabbits. On the other hand, there was significant increase in the mean value of seminal plasma AFB<sub>1</sub> level and abnormal sperm forms of the post-treatment rabbits.

These results could be explained by Aflatoxin induced reduction of serum testosterone (Salem et al., 2001; Verma and Nair, 2002) and also by direct toxic effect of Aflatoxin on testicular tissue and mutagenesis (Verma, 2004). High seminal fluid AFB<sub>1</sub> level could be explained as, in a normal situation, ingested Aflatoxin is metabolized at the liver to intermediate and end products, which are more water soluble and easily excreted via urine. When liver function becomes inefficient or impaired, accumulation of Aflatoxins occurs. The translocation of Aflatoxin B<sub>1</sub> from the blood to semen through the blood testis barrier was very effective (Uriah et al., 2001). Marvan et al. (1983) found that, among all tissues, AFB<sub>1</sub> concentration was the highest in the gonads. Petr et al. (1995) conducted a study on the Chinese hamster. The authors detected a free AFB<sub>1</sub> in the testis after a single i.p dose of 0.1 mg of AFB<sub>1</sub>/Kg from minutes up to 8-10 hours after injection. The results are in agreement with the results recorded by Egbunike (1985) where disruption of spermatogenesis, androgen synthesis and sperm function were observed in male mice treated with AFB<sub>1</sub> at 50-60 mg/kg

body weight/day for 30 days.

Ibrahim and Salim (1994) observed gross reduction in serum testosterone level after treatment of male rats with Aflatoxin. Salem et al. (2001) conducted a research on mature male rabbits to detect the effect of Aflatoxin B1 on semen quality. Significant decreases in ejaculate volume, sperm concentration, sperm motility index, and semen initial fructose concentration were detected after treatment of animals with two sublethal doses of Aflatoxin B<sub>1</sub>.

Adedara et al. (2014) conducted a study on Leydig cells, isolated from 35-day-old male Long-Evans rats, after incubation with AFB<sub>1</sub> at different doses. AFB<sub>1</sub> suppressed testosterone secretion in a dose-dependent manner.

Ataman et al. (2014) conducted a study on Merino rams to study the effect of Aflatoxin (AF) on spermatologic, biochemical, and testis parameters in rams. The percentage of motile sperm was lower and the percentages of abnormal sperm, sperm with damaged acrosomes, and dead sperm were greater in the Aflatoxin treated group.

The present study showed testicular regression as there were significant decreases in the mean value of seminiferous tubules area and significant increase in the mean value of interstitial area in the treat-

ed rabbits. The result of testicular regression is in agreement with Doerr and Ottinger (1980), where aflatoxicosis was induced in young Japanese quail. There were significant decreases in testicular weights relative to body weight in a period of six weeks. Piskac et al. (1982) conducted a study on male rats and pigs. The testes showed different degrees of dystrophy leading to the destruction and atrophy of spermiogenic epithelium and edema in the tissue.

The present results agreed with the results recorded by Ortatatli et al., (2002) on adult rooster males where there were significantly atrophied testes and absence of spermatogenesis of all AF-treated groups of birds.

On the other hand a study conducted by Lakkawar et al. (2004) on New Zealand white rabbits in which animals were fed an Aflatoxin B<sub>1</sub> (AFB<sub>1</sub>) contaminated diet. Mild testicular atrophy with other signs of aflatoxicosis was found. Ahmed et al. (2012) found that there were dose dependent histopathological changes varied from mild testicular degeneration to a complete atrophy of seminiferous tubules and loss of all stages of spermatogenesis.

The study of Shapour and Leila (2013) evaluated the chronic effects of Aflatoxin

B<sub>1</sub> on spermatogenic cell series in adult Wistar male rats. The authors concluded that the oral administration of Aflatoxin B<sub>1</sub> can decrease spermatogenic cells in a dose dependent manner.

### **CONCLUSION**

The present work showed significant increase in seminal plasma AFB<sub>1</sub> level in the infertile human group. The increased AFB<sub>1</sub> level affected significantly semen parameters.

Experimental results showed significant negative correlation between the seminal AFB<sub>1</sub> level and sperm concentration, sperm viability and total sperm motility meanwhile significant positive correlation with abnormal sperm forms was detected. Histopathological examination showed degeneration of seminiferous tubules, which increased by increasing duration of treatment. The tubules showed absence of mature sperms with appearance of uninucleated and multinucleated giant cells. Epididymal epithelium showed vaculation and degeneration which increased by increasing the duration of treatment.

### **RECOMMENDATIONS**

It is advised to measure Aflatoxin B<sub>1</sub> level in seminal plasma of infertile male as increased Aflatoxin B<sub>1</sub> level can be consid-

ered as one of the causes of male infertility.

#### REFERENCES

**Adedara, I.A.; Nanjappa, M.K.; Farombi, E.O. and Akingbemi, B.T. (2014):** "Aflatoxin B<sub>1</sub> disrupts the androgen biosynthetic pathway in rat Leydig cells". *Food Chem. Toxicol.*, 65:252-259.

**Agnes, V.F. and Akbarsha, C.A. (2003):** "Spermatotoxic effect of Aflatoxin B<sub>1</sub> in the albino mouse". *Food and Chemical Toxicology*, 4:119-130.

**Ahmed, K.A.; El Mahady, M.M.; Badawy, S.A.; et al. (2012):** "Pathological consequences of Aflatoxins in male rabbit: Cellular, genetic and oxidative damage". *Global Veterinaria*, 9(1):42-52.

**Amann, R.P. (1982):** " Use of animal models for detecting specific alterations in reproduction". *Fundam. Appl. Toxicol.*, 2:13-26.

**Ataman, M.B.; Dönmez, H.H., Dönmez, N.; et al. (2014):** "Protective effect of esterified glucomannan on Aflatoxin-induced changes in testicular function, sperm quality, and seminal plasma biochemistry in rams". *Theriogenology*, 81: 373-380.

**Bennett, J.W. and Klich, M. (2003):** "Mycotoxins". *Clinical Microbiology Re-*

*views*, 16(3):497-516.

**Corcuera, L.A.; Ibáñez-Vea, M.; Vettorazzi, A.; et al. (2011):** "Validation of a UHPLC FLD analytical method for the simultaneous quantification of Aflatoxin B<sub>1</sub> and ochratoxin A in rat plasma, liver and kidney". *Journal of Chromatography*, 879:2733-2740.

**De Kretser, D.M. and Kerr, J.B. (1994):** The cytology of testis. In: *The Physiology of Reproduction*. Knobil, E.: Neill, J. D. (Eds), New York: Raven Press Ltd, Chapter 20, P.P. 1117-1290.

**Denissenko, M.F.; Cahill, J.; Koudriakova, T.B.; et al. (1999):** "Quantitation and mapping of Aflatoxin B<sub>1</sub>-induced DNA damage in genomic DNA using Aflatoxin B<sub>1</sub> 8, 9-epoxide and microsomal activation systems". *Mutat Res.*, 425: 205-211.

**Doerr, J.A. and Ottinger, M.A. (1980):** "Delayed reproductive development resulting from aflatoxicosis in juvenile Japanese quail". *Poult Sci.*, 59:1995-2001.

**Egbunike, G.N. (1985):** "Sperm maturation and storage in the male rat after acute treatment with Aflatoxin B<sub>1</sub>". *Andrologia*, 17:379-382.

**Egbunike, G.N.; Emerole, G.O.; Aire, T.A. and Ikegwonu, F.I. (1980):** "Sperm production rates, sperm physiology and

fertility in rats chronically treated with sublethal doses of Aflatoxin B<sub>1</sub>". *Andrologia*, 12:467-475.

**Faridha, A.; Faisal, K. And Akbarsha, M. (2006):** "Duration-dependent histopathological and histometric changes of Aflatoxin B<sub>1</sub>-treated mice". *J. Endocrinol. Reprod.*, 10(2):117-133.

**Hafez, A.H.; Gomma, A.; Mousa, S.A. and Megalla, S.E. (1983):** "Aflatoxin and aflatoxicosis: The effect of dietary Aflatoxins on adult fertile male and female rabbits at various reproductive conditions". *Mycopathologia*, 83(3):183-186.

**Hussein, H.S. and Brasel, J.M. (2001):** "Toxicity, metabolism, and impact of mycotoxins on human and animal health". *Toxicology*, 167:101-134.

**Ibrahim, M.S. and Salim, M.I. (1994):** "Effect of Aflatoxin B<sub>1</sub> on steroid hormones in young male rats". *Journal of Environmental Science*, 7:125-140.

**International Rabbit Reproduction Group (2005):** "Guidelines for the handling of rabbit bucks and semen". *World Rabbit Sci.*, 13:71-91.

**Lakkawar, A.W.; Chattopadhyay, S.k. and Johri, T. S. (2004):** " Experimental Aflatoxin B<sub>1</sub> toxicosis in young rabbits - a clinical and patho-anatomical study". *Slov.*

*Vet. Res.*, 41(2):73-81.

**Louis-Marie, H. and Jaingline, F. (2009):** Improvement of rabbit production. In: *Rabbit Biotechnology, Rabbit Genomics, Transgenesis Cloning and Models*. Louis-Marie, H. and Jaingline, F. (Eds), New York: Springer Dordrecht Heidelberg London, 1<sup>st</sup> edition, Chapter 2, P.P. 3-6.

**Marvan, F.; Vernerova, E.; Samek, M.; et al. (1983):** "Aflatoxin B<sub>1</sub> residues in the organs of young poultry". *Biologické Chem. Vet. (Praha)*, 24:85-92.

**Morton, D. (1988):** "The use of rabbits in male reproductive toxicology". *Environmental Health Perspectives*, 77:5-9.

**Ortatatli, M.; Ciftci, M.K.; Tuzcu, M. and Kaya, A. (2002):** "The effects of Aflatoxin on the reproductive system of roosters". *Res. Vet. Sci.*, 72:29-36.

**Peterson, S.W.; Ito, Y.; Horn, B.W.; and Goto, T. (2001):** "Aspergillus bombycis, a new aflatoxigenic species and genetic variation in its sibling species, *A. nomius*". *Mycologia*, 93:689-703.

**Petr, T.; Barta, I. and Turek, B. (1995):** "In vitro effect of mutagenic activity of Aflatoxin B<sub>1</sub>". *Hyg. Epidemiol. Microbiol. Immunol. (Prague)*, 34:123-128.

**Pícha, J.; Cerovsky, J. and Píchová, D. (1986):** "Fluctuation in the concentration of

sex steroids and Aflatoxin B<sub>1</sub> in the seminal plasma of boars and its relation to sperm production". *Vet. Med. (Praha)*, 31 (6):347-357.

**Pier, A.C. (1992):** "Major consequence of aflatoxicosis in animal production". *J. Animal Sci.*, 70(12):3964-3967.

**Piskac, A.; Drabek, J.; Halouzka R. and Groch, L. (1982):** "The effect of long term administration of Aflatoxins on the health status of male rats and pigs with respect to morphological changes in the testes". *Vet. Med.*, 27:101-111.

**Salem, M.H.; Kamel, K.I.; Yousef, M.I.; et al. (2001):** "Protective role of ascorbic acid to enhance semen quality of rabbits treated with sublethal doses of Aflatoxin B<sub>1</sub>". *Toxicology*, 162:209-218.

**Shapour, H. and Leila, R. (2013):** "Effects of Aflatoxin B<sub>1</sub> on the growth processes of spermatogenic cell series in adult male rats comparative". *Clinical Pathology*, 22(4):555-562.

**Smith, J.T. and Mayer, D.T. (1955):** "Evaluation of sperm concentration by the haemocytometer method". *Fertile. Steril.*, 6:271-275.

**Sun, E. L.; and Gondos, B. (1986):** "For-

mation of the blood-testis barrier in the rabbit". *Cell Tissue Res.*, 243:575-578.

**Uriah, N.; Ibeh, I.N. and Oluwafemi, F. (2001):** "A Study on the impact of Aflatoxin on human reproduction. *African Journal of Reproductive Health*". 5(1):106-110.

**Verma, R.J. (2004):** "Aflatoxin causes DNA damage". *Int. J. Hum. Genet.*, 4 (4):231-236.

**Verma, R.J. and Nair, A. (2002):** "Effect of Aflatoxins on testicular steroidogenesis and amelioration by vitamin E". *Food and Chemical Toxicology*, 40:669-672.

**Williams, J.; Phillips, T.; Jolly, P.; et al. (2004):** "Human aflatoxicosis in developing countries: A review of toxicology, exposure, potential health consequences, and interventions". *Am. J. Clin. Nutr.*, 80 (5):1106-1122.

**World Health Organization and Department of Reproductive Health and Research (2010):** WHO laboratory manual for the examination and processing of human semen (fifth edition).

**Zohri, A. A. (1990):** Mycoflora and mycotoxins in some meat products. PhD Thesis, Botany Department, Fac. Sci., Assuit

## التأثيرات السامة للأفلاتوكسين B<sub>1</sub> على الحيوانات المنوية فى عينة من سكان محافظة سوهاج وفى الأرانب

المشركون فى البحث

سهير على محمد  
مهنا عبد الحميد هلال  
خالد السيد أبو الحجاج  
إيمان محمد صلاح\*  
نهى الضبع عثمان\*

من قسمي الطب الشرعي والسموم الاكلينيكية\* والهستوباثولوجى - كلية الطب - جامعة سوهاج

تعتبر مجموعة الأفلاتوكسين من اشهر الفطريات. ويعتبر الأفلاتوكسين B<sub>1</sub> من أقوى المسرطنات الطبيعية فى الانسان و الحيوان. و قد ثبت ان التركيزات المنخفضة من الافلاتوكسين وخاصة AFB<sub>1</sub> يمكن ان تؤثر بشكل واضح على التناسل فى الذكور ومن ثم الخصوبة. و يهدف هذا البحث الي دراسة تأثير الأفلاتوكسين B<sub>1</sub> على الجهاز التناسلي الذكري، اكلينيكياً على الإنسان وتجريبياً على الأرانب.

تم تطبيق هذه الدراسة على عدد 100 فرد من الذكور من المتردين على عيادة التناسلية بمستشفيات سوهاج الجامعية. تم تقسيمهم طبقاً لتحليل السائل المنوى الى مجموعتين متساويتين بكل منها 50 فرداً. و كان تحليل السائل المنوي للمجموعة الأولى طبيعياً، بينما كان تحليل المجموعة الثانية غير طبيعي. وقد تم التحليل الكمي للأفلاتوكسين B<sub>1</sub> ببلازما السائل المنوي لكلتا المجموعتين.

بالنسبة للدراسة التجريبية للحيوانات فقد استمرت 63 يوماً وقد اشتملت على عدد 45 ذكر من أرانب النيوزيلاندى الأبيض البالغة، والتي قسمت بالتساوي إلى ثلاث مجموعات، وقسمت كل مجموعة بالتساوي إلى ثلاث مجموعات فرعية، واعتبرت المجموعة الفرعية الأولى مجموعة ضابطة سالبة تتناول عليقة تجارية فقط، بينما اعتبرت المجموعة الفرعية الثانية مجموعة ضابطة موجبة تتناول المادة المذيبة و المجموعة الفرعية الثالثة تعامل بالأفلاتوكسين B<sub>1</sub> بتركيز 20 ميكروجرام/ كجم من وزن الجسم لفترات زمنية مختلفة لمختلفة لكل مجموعة اساسية (30, 48, 63 يوم). تم إجراء التحليل الكمي لنسبة الأفلاتوكسين B<sub>1</sub> بالسائل المنوى للانسان و الحيوان باستخدام جهاز الكروماتوجرافي عالي الكثافة.

أوضحت نتائج الدراسة على الانسان الآتي: ارتفاع ذو دلالة احصائية فى مستوى الأفلاتوكسين B<sub>1</sub> بالسائل المنوى للمجموعة التي تعانى من العقم. وجود ارتباط معنوي سالب بين متوسط الأفلاتوكسين B<sub>1</sub> وتركيز الحيوانات المنوية بالمل (X ١٠<sup>-٦</sup>) وكلا من نسبتي الحركة التقدمية والكلية للحيوانات المنوية. وعلى الجانب الآخر، لوحظ وجود ارتباط معنوي موجب بين مستوى الأفلاتوكسين B<sub>1</sub> ونسبة الحيوانات المنوية الشاذة، أوضحت نتائج الارانب المعاملة وجود انخفاض معنوي فى متوسط تركيز الحيوانات المنوية بالمل (X ١٠<sup>-٦</sup>) ونسبة حيوية الحيوانات المنوية (X ١٠<sup>-٦</sup>) نسبة حركة الحيوانات المنوية (%). و هذا الانخفاض مرتبط بالزيادة المعنوية لمتوسط مستوى تركيز الأفلاتوكسين B<sub>1</sub> ببلازما السائل المنوي (بيكوجرام / مل). وأشارت التحاليل الهستولوجية إلى وجود تدهور واضح بالأنايب المنوية، والذي زاد بزيادة الفترة الزمنية للمعاملة. وأظهرت الأنايب غياب الحيوانات المنوية الناضجة مع ظهور الخلايا العملاقة وحيدة النواة والخلايا متعددة الأنوية. ولوحظ تدهور بظلامية البربخ والتي زادت بزيادة فترة المعاملة.